

## **Electron Microscopic Study of Contracted Scarred Skin Under Distraction Produced by Ilizarov External Fixators**

FAYEZ EL-DEEB, M.D., F.R.C.S.

*The Department of Plastic Surgery, Ahmad Maher Teaching Hospital, Cairo.*

### **ABSTRACT**

A new application of Ilizarov external fixators was used to correct post-burn contracture deformity of the wrist joint, by soft tissue distraction histogenesis. While distraction osteogenesis for bone lengthening and soft tissue expansion for soft tissue lengthening have been widely practiced, no previous experience was found in the literature about lengthening of scarred skin. Ilizarov apparatus was applied to eight post-burn flexion-contraction-deformed wrist joints in five patients: four females and one male, with the ages of 14, 15, 18, 20 and 25 years. Distraction was carried out at the rate of 1 mm/day and stopped at full correction of the deformity. The apparatus was removed four weeks after full correction. The period of distraction ranged between four and seven weeks. Full correction was obtained in seven wrists and a satisfactory correction in the eighth. Minor complications were encountered as infection at a K wire site or slight separation of radial epiphysis, which were managed by simple measures. A biopsy was taken from the scarred skin at the beginning and at the end of the distraction and examined under the Electron Microscope. Collagen fibers were found to be fragmented by the distraction. Signs of immaturity and increased mitosis were found. Due thanks are to the staff of the Electron Microscopic unit in the National Cancer Institute in Cairo for their great help.

### **INTRODUCTION**

Post-burn contracture deformities constitute an infrequent disfiguring disability, received in significant numbers every year in the plastic and reconstructive surgical units. These deformities were usually treated in a single or multiple stages. It has been the usual practice to do release of the skin with a skin graft or a flap across the joint [1]. The surgical release incisions were followed by splinting of the part at its maximum stretch and followed in 3-4 weeks by re-splinting at a higher degree of stretch. The patients, usually, were not satisfied because of the disfigurement and residual contraction.

In 1951, Professor Gavriil Abramovich Ilizarov from kurgan in the ex-Soviet Union developed a

circular external fixator for the treatment of fractures [2,3].

Through controlled, mechanically applied tension stress, Ilizarov was able to show that bone and soft tissue can be made to regenerate in a reliable and reproducible manner. Over the next 41 years until his death in 1992 at the age of 71, he developed countless clinical applications of bone and soft tissue regeneration [4].

The mechanisms of new bone formation under controlled mechanical distraction as pioneered by Ilizarov are relatively well understood and have been reproduced by several investigators [5,6]. Ilizarov [2] has investigated the effects of distraction on skin, muscle, tendon, fascia, blood vessels, lymphatic channels and peripheral nerves.

Although different tissues react, to continuous stretch, in different ways, there are two predominant mechanisms at play: reorganization of collagen and neo-histogenesis. For example, the initial reaction of fascia to closed distraction is reorientation of its collagen network to stretch [7]. This can be likened to pulling on a fisherman's net. The crosshatches that form square holes in the net reorient to form diamond-shaped holes and eventually just slits. After collagen fiber reorientation, increased fibroblastic activity is seen [4].

Dyachkova [7] showed that muscle also responds initially by stretching without cell proliferation, followed by a combination of stretching and a cellular response. The cellular response is mixed, First, there is a recruitment of cells, as evidenced by increased numbers of satellite cells seen. These undergo neohistogenesis and contribute to the growth in length of new muscle. Similar findings were reported by Appell and coworkers in athletes

[8]. Second, there is an addition of sarcomeres to existing muscle cells. Radiologic markers were placed on both muscle and fascia in order to determine the level at which the lengthening was occurring [9]. For the first 20% of growth and lengthening of the muscle, the radiologic markers moved apart evenly between the muscle tendon junctions. After 20% of lengthening of the muscle was achieved, there was greater lengthening seen at the level of the bone distraction than at other levels in the muscle. Between 20% and 25% lengthening increased damage was noted in the muscle structure [10].

This was followed by a change in histology and finally, by alteration in the total morphology of the muscle. The recovery of the muscle occurred in reverse order. There was first a recovery of the morphology, followed by the histology and only at a very late stage, the electrophysiology.

Peripheral nerves are seen to undergo change under distraction as well [11,12]. New schwann cells and active myelination can be observed in the peripheral nerves. Electron microscopic morphologic features typical of fetal tissue but atypical of adult tissue are observed in the nerves, muscles and most of the soft tissues. Ilizarov [3] claimed that "tension stress" stimulates tissue to regress into a fetal state with the regenerate potential of fetal tissue.

Tissue expansion has been widely practiced. Histologic changes in tissue expansion can be summarized as follows [13,14]. The epidermis thickens by cellular hyperplasia and intercellular spaces are narrowed. The basilar layer shows an increased rate of mitosis. The dermis undergoes increased fibroplasia, increased collagen deposition and realignment of collagen fibers [15]. Dermal thickness decreases and the elastic fibers are fragmented. Dermal appendages are separated from one another without significant morphologic changes. Muscle becomes thin and compacted with abnormal sarcomeres and myofibrils and increased mitochondria. Adipose cells atrophy with some permanent loss. Vascularity increases dramatically [16]. The number and caliber of capillaries increase. Tissue response is more dramatic to rapid expansion. Excessively rapid and violent expansion can result in irreversible damage to tissue.

This paper is studying the Electron Microscopic changes in the contracted scarred skin produced by Ilizarov external fixator distraction for treating post-burn contracture deformities at the wrist joint.

## MATERIAL AND METHODS

Eight wrist joints in five patients with post-burn flexion contracture deformity, were studied. The ages of the patients ranged from 14 to 25 years with a mean age of 18.4 years. Four of the patients were females and one was a male. They presented after different periods of time ranging from seven to thirty-six months from their burning incident. X-ray examination of the wrist joints showed normal space and outline in the seven patients who presented several months after the burn, while an abnormal joint space and outline was found in the eighth patient who presented three years after the burn.

The patients were referred by distant hospitals or private doctors after receiving dressing management in the distant areas. Flexion deformity ranged from 70°-100°. Five different orthopedic surgeons applied the apparatus.

Ilizarov external fixators were applied, under general anesthesia in the form of rings or half rings, fixed with K wires and half pins and connected with rods, to correct deformity of the wrist. The apparatus was fixed to the bones either with K wires only or K wires and half pins. Distally, the K wires were passed through all the metacarpals, the half pin is fixed to the second or third metacarpal. Proximally, the K wires were passed through both radius and ulna. When K wires are used alone, two are required on each side of the deformity, when K wires and half pins are used, one K wire and one half pin are required on each side of the deformity (proximal and distal). A waiting period of 5 days was left before starting distraction. The nut was rotated to allow one millimetre lengthening per day with the vector of the distraction force along the axis of the forearm and wrist joint. As there is no past experience in literature of exclusive soft tissue distraction of scars, an arbitrary modification of the way used in distraction osteogenesis was used, where no splint was applied after removing the apparatus. Special emphasis is made on active physiotherapy e.g. dynamic splints, after the removal of the fixators.

Cleansing and dressing around the wires and half pins was done every other day. X ray was done every two weeks to check the position of the bones at the joint.

Antibiotic prophylaxis was given at the time of insertion and removal. The time taken to correct

the deformity ranged between 4 and 7 weeks. The apparatus was removed four weeks after full correction.

An axial elliptical skin biopsy was taken from the scarred contracted skin at the beginning and at the end of the distraction and examined under the Electron Microscope.

## RESULTS

Electron Microscopic pictures of the scarred skin showed the collagen fibers that were intact at the beginning of the distraction to be fragmented

at the end of the distraction. Signs of immaturity and increased mitosis were seen.

The flexion contracture deformity of the wrist was corrected completely in 7 hands and satisfactorily corrected in one hand. The pain caused by the apparatus could be managed with the usual pain killer tablets.

Pyogenic infection occurred around one of the K wires for which repeated cleansing with betadine and dressing was done, which resulted in clearing of the infection. Slight separation of the epiphysis of the distal end of the radius was noticed on the X-ray of one wrist, which required no intervention.

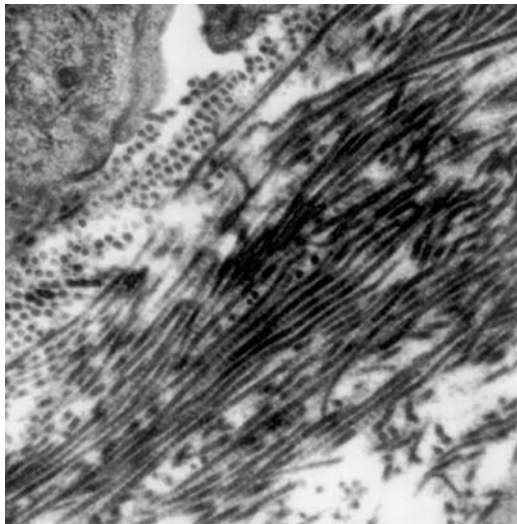


Fig. (1-A)

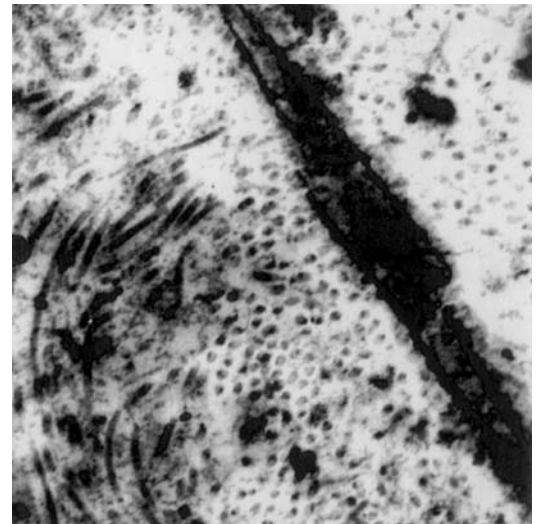


Fig. (1-B)

Fig. (1): Electron-micrograph of scar tissue at the beginning (a) and the end (b) of distraction.

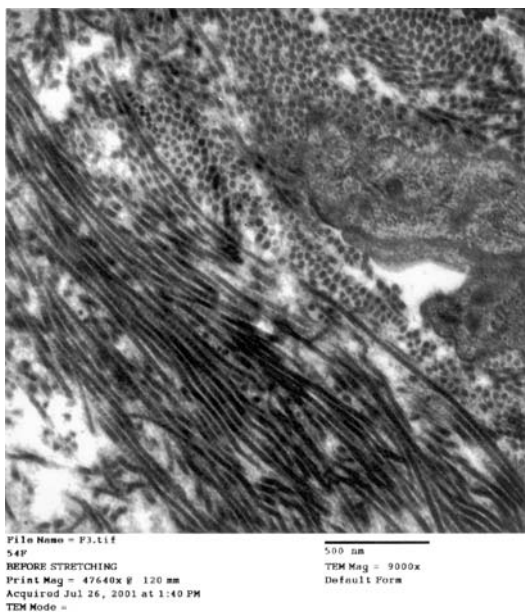


Fig. (2-A)

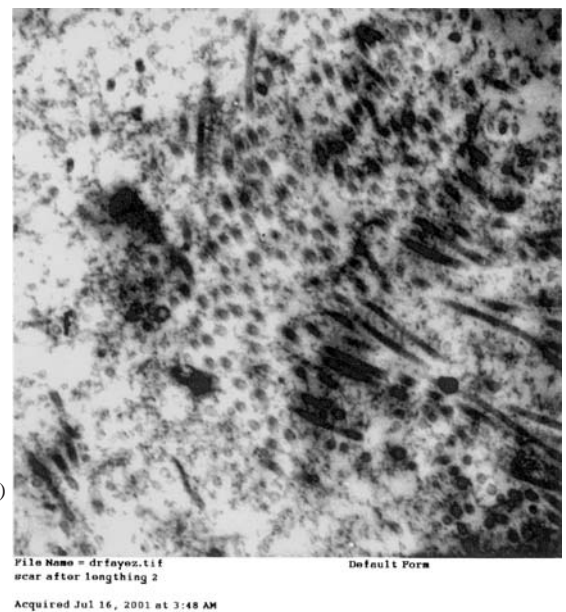


Fig. (2-B)

Fig. (2): Electron-micrograph of scar tissue at the beginning (a) and the end (b) of distraction.



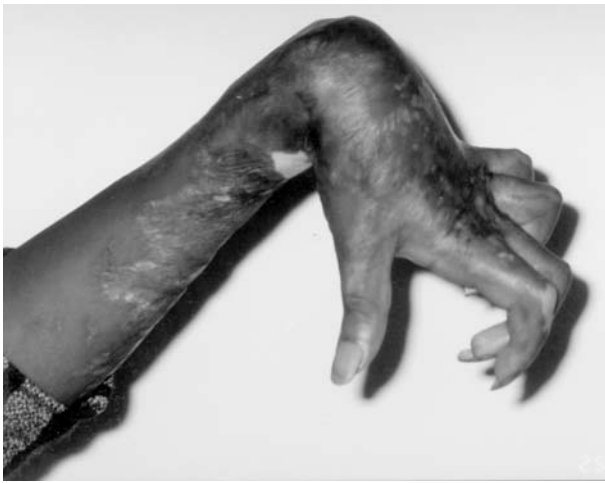

Fig. (3-A)

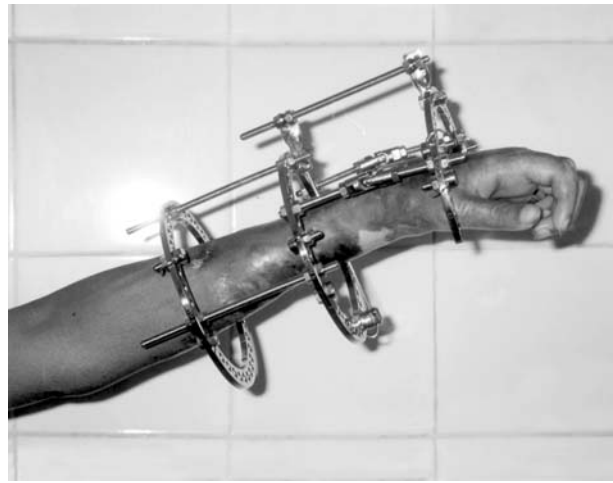


Fig. (3-B)

Fig. (3): Wrist joint before (a) and after distraction (b).

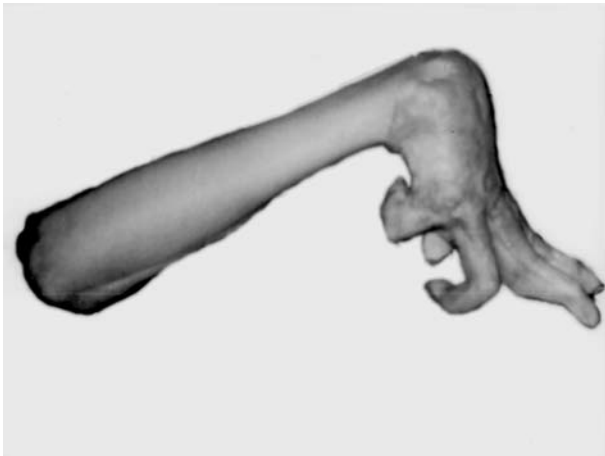


Fig. (3-A)

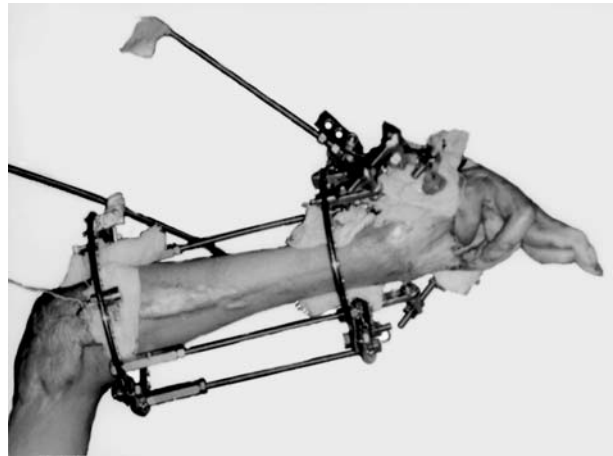


Fig. (3-B)

Fig. (4): Another wrist joint before (a) and after distraction (b).

## DISCUSSION

The Electron Microscopic changes in contracted scarred skin under distraction are found to be comparable to the fascial tissue changes and incomparable to the normal skin changes under distraction.

Correction of the contracture deformity by Ilizarov soft tissue distraction histogenesis saves the patient the disfigurement and the residual deformity.

The previous traditional incision release and splinting for these deformities resulted in damage to the neurovascular bundle and we came across few patients with foot drop after incision release of a knee contracture which resulted in nerve palsy. The effects of sudden overstretching on the neurovascular bundle and the tendons are unpredictable

and unsafe in relation to the predictable and safer gradual stretch by Ilizarov fixators [17].

### Conclusion:

The Electron Microscopic changes in scarred skin under distraction are governed by the same mechanisms as the fascial tissue.

Ilizarov soft tissue distraction histogenesis is the best modality of treatment for post-burn contracture deformity of the wrist joint. The facility of the Ilizarov equipment and the expertise required to apply the apparatus are worth-having.

## REFERENCES

- 1- Settle J.A., et al.: Principles and practice of burns management. Churchill Livingstone, 1996.

- 2- Ilizarov G.A.: The tension-stress effect on the genesis and growth of tissues. Part 1: The influence of stability of fixation and soft tissue preservation. Clin. Orthop., 238: 249-281, 1989.
- 3- Ilizarov G.A.: The tension stress effect on the genesis and growth of tissue Part 2: The influence of the rate and frequency of distraction. Clin. Orthop., 238: 263-285, 1989.
- 4- Mosby-Year Book, Inc., Advances in Operative Orthopaedics, Vol. 1, 1993.
- 5- Aronson J., Harrison B., Cannon D.J., et al.: Mechanical induction of osteogenesis the importance of pin rigidity. J. Pediatr. Orthop., 8: 396, 1988.
- 6- Bagnoli G., Penna G., Landini A., et al.: Experimental study on bone formation under straining forces: Clinical and radiologic features. Policlinico, 91: 908-913, 1984.
- 7- Dyachkova G.V. and Utenkin A.A.: Extensibility of superficial fascia in elongation of the leg in experiment. Ortop. Travmatol. Protez, 41: 44-47, 1980.
- 8- Appell H.J., Forsberg S. and Hollman W.: Satellite cell activation in human skeletal muscle after training. Evidence for muscle fibre neoformation. J. Sports Med. Phys. Fitness, 9: 297-299, 1988.
- 9- Paley D.: Current techniques of limb lengthening. J. Pediatr. Orthop., 8: 73-92, 1988.
- 10- Aihio A., Berg G., Karaharju E., et al.: Filling of a bone defect during experimental osteotaxis distraction. Acta Orthop. Scand., 53: 29-34, 1982.
- 11- Smirnova L.A., Belenko L.I., Mazhara N.N., et al.: Morphologic changes of nerve trunks and neuromuscular apparatus of the leg during its closed elongation. Ortop. Travmatol. Protez, 43: 37-44, 1972.
- 12- Kojimoto H., Yasvi N., Goto T., et al.: Bone lengthening in rabbits by callus distraction. J. Bone Joint Surg. Br., 70B: 543-549, 1988.
- 13- Pasyk K.A., Argenta L.C. and Austad E.D.: Histopathology of human expanded tissue. Clin. Plast. Surg., 14: 435-445, 1987.
- 14- Pasyk K.A., Argenta L.C. and Hassett C.: Quantitative analysis of the thickness of human skin and subcutaneous tissue following controlled expansion with a silicone implant. Plast. Reconstr. Surg., 81: 516, 1988.
- 15- Austad E., et al.: Histomorphologic evaluation of guinea pig skin and soft tissue after controlled tissue expansion. Plast. Reconstr. Surg., 70: 704, 1982.
- 16- Cherry G.W., Austad E., Pasyk K., et al.: Increased survival and vascularity of random pattern skin flaps elevated in controlled, expanded skin. Plast. Reconstr. Surg., 72: 680, 1983.
- 17- El-Deeb F.: Ilizarov soft tissue distraction histogenesis for post-burn contracture deformity of the wrist joint. Sci. Med. J. ESCME, Vol. 11, No. 4, Oct., 1999.